No Association Between Fibrosis on Magnetic Resonance Imaging at Return to Play and Hamstring Reinjury Risk

Gustaaf Reurink,*†‡ MD, Emad Almusa,§ MD, Gert Jan Goudswaard,‖ MD, Johannes L. Tol,‖ MD, PhD, Bruce Hamilton,¶ MD, PhD, Maarten H. Moen,‡# MD, PhD, Adam Weir,‖ MD, PhD, Jan A.N. Verhaar,† MD, Prof., and Mario Maas,** MD, Prof.
Investigation performed at Erasmus Medical Centre, Rotterdam, the Netherlands, and Aspetar Orthopaedic and Sports Medicine Hospital, Doha, Qatar

Background: Connective tissue scar (fibrosis) is a common finding on magnetic resonance imaging (MRI) after recovery from acute hamstring injuries. Fibrosis has been suggested as a predisposing factor for reinjury, but evidence from clinical studies is lacking.

Purpose/Hypothesis: The aim of this study was to examine the association between the presence of fibrosis on MRI at return to play after an acute hamstring injury and the risk of reinjury. The hypothesis was that fibrous tissue on MRI was associated with an increased reinjury risk.

Study Design: Cohort study; Level of evidence, 3.

Methods: Magnetic resonance images were obtained from 108 consecutive athletes with modified Peetrons classification grade 1 or 2 hamstring injuries within 5 days of injury and within 7 days of return to play. The presence and extent of abnormally low signal intensity in the intramuscular tissue on MRI, suggestive of fibrosis, were assessed on both T1- and T2-weighted images. Reinjuries were recorded over a 1-year follow-up period. The association between fibrosis and reinjury risk was analyzed with a Cox proportional hazards model.

Results: The MRIs of the initial injury showed 45 (43%) grade 1 and 63 (57%) grade 2 injuries. Median time of return to play was 30 days (interquartile range [IQR], 22-42 days). At return to play, 41 athletes (38%) had fibrosis on MRI with a median longitudinal length of 5.8 cm (IQR, 3.3-12.5 cm) and a median volume of 1.5 cm^3 (IQR, 1.5-3.9 cm^3). In athletes with fibrosis, 24% (10/41) sustained a reinjury, and in the subjects without fibrosis, 24% (16/67) had a reinjury, resulting in a hazard ratio of 0.95 (95% CI, 0.43-2.1; P = .898).

Conclusion: Fibrosis is commonly seen on MRI at return to play after grade 1 or 2 hamstring injuries but is not associated with reinjury risk.

Keywords: hamstring injury; fibrosis; reinjury; magnetic resonance imaging; return to play

Acute hamstring injuries are the most common injuries in sports such as football, track and field, and Australian rules football.[1,10,24] These injuries have a high rate of reinjury, ranging from 14% to 63% in the first year after return to play (RTP).[6,8,25,32] Reinjuries are often more severe than the initial injury and are associated with a longer absence from play.[6,10] A premature RTP[17,23] and scar tissue formation[13,17,22,33,34] are the most frequently suggested predisposing factors for reinjury.

Muscle regeneration after injury follows a fairly constant sequence of degeneration, inflammation, and regeneration.[13,19] From 2 to 3 days after injury, formation of a connective tissue scar (fibrosis) occurs at the site of the injury. During the following weeks, regenerating myofibers begin to penetrate, and the fibrous tissue diminishes in size over time.[13,19] While formation of fibrous tissue is an essential component of muscle healing, excessive formation is suggested to impair functional recovery.[13,18,19,34] Persisting fibrosis has been shown to alter muscle contraction mechanics, generating greater tissue strain near the site of prior musculotendinous junction injury of the biceps femoris.[34] While these theoretical arguments suggest that fibrosis may predispose an athlete to reinjury, a recent systematic review highlighted that no clinical studies have examined the association between fibrosis and hamstring reinjury.[8]

Previous studies have shown that fibrosis, which has predominately low signal intensity on all sequences on magnetic resonance imaging (MRI), is common in grade 1 and 2 hamstring injuries at RTP[29,35] and can persist in the long term.[31,33] A recent observational study reported that 42% of hamstring injuries had fibrosis on MRI at RTP.[29] Because of the limited number of reinjuries, there was insufficient power to study any association between the presence of fibrous tissue and the risk of reinjury. We therefore conducted the present study with a larger sample

The American Journal of Sports Medicine, Vol. 43, No. 5
DOI: 10.1177/0363546515572603
© 2015 The Author(s)

size by pooling data from 2 randomized trials with a prolonged follow-up period.

The aim of this study was to examine the association between MRI-determined fibrosis and the risk of reinjury in athletes who have clinically recovered from an acute hamstring injury. Our hypothesis was that fibrous tissue on MRI was associated with an increased reinjury risk.

MATERIALS AND METHODS

Subjects

The patients in this study were pooled from 2 double-blind, randomized controlled trials on the effect of platelet-rich plasma in hamstring injuries (Dutch trial register number 2771 and ClinicalTrial.gov number NCT01812564). The first was completed in November 2013 (Dutch cohort). In the first study, the intervention group received two 3-mL ultrasound-guided injections of platelet-rich plasma (Autologous Conditioned Plasma, Biocore; Arthrex Inc) and the control group received two 3-mL injections of saline at the site of the injury. This study found no difference in time to RTP and reinjury rate between the group that received PRP injections and the control group that received saline injections.[28]

The second randomized controlled trial is an ongoing study that started in November 2009 (Qatari cohort). In this study, subjects were randomized into 3 groups: 1 group received a 3-mL injection of platelet-rich plasma (Biomet Recover), 1 group received a 3-mL injection of platelet-poor plasma, and 1 group received no injection. All subjects completed a standardized physical therapy program, including range of motion exercises, progressive strength exercises, core stability training, and agility exercises.

The eligibility criteria for the present study are presented in Table 1. In the Dutch cohort, the functional criteria-based rehabilitation program was supervised by a sports physical therapist. Clearance for RTP was given once the athlete successfully completed the physical therapy program and functional sport-specific activities. In the Qatari cohort, the guideline criteria to assist RTP decision included successfully and asymptomatically completing the functional criteria–based physical therapy program, including a final supervised sport-specific (outdoor) training phase.[38] After RTP clearance, athletes were advised to complete 5 days of team training before participating in partial match play.

At inclusion, informed consent was obtained from all patients. Approval was obtained from the Regional Ethical Committee of South West Holland and the Ethical Committee of Aspetar, Qatar Orthopaedics and Sports Medicine Hospital.

Magnetic Resonance Imaging

In each subject, an MRI of the injury was performed twice: once within 5 days from the time of initial injury and again within 1 week of RTP. The MRI of the initial injury was performed before any injection procedure.

MRI Protocol. Two comparable MRI protocols were used. The protocol in the Dutch cohort was a modified version of the protocol described by Askling et al.[2] To locate the area of the injury, the entire hamstring of the injured limb was visualized by obtaining coronal and sagittal short-tau inversion recovery (STIR) images from the ischial origin of the hamstring muscles to insertion on the fibula and the tibia (repetition time [TR]/echo time [TE], 3500/31 ms; field of view [FOV], 300 mm; matrix, 256 × 320). Subsequently, transverse STIR (TR/TE, 3500/31 ms; FOV, 300 mm; matrix, 205 × 256), T1-weighted images (TR/TE, 500/12 ms; FOV, 300 mm; matrix, 355 × 448), and T2-weighted images (TR/TE, 4080/128 ms; FOV, 300 mm; matrix, 355 × 448) were obtained from the injured area. The slice thickness for all sequences was 5 mm. The MRI scans were obtained with a 1.5-T magnet system (Magnetom Essenza, Siemens) with the use of a body matrix coil.

In the Qatari cohort, MRI of the hamstring muscles was conducted with a 1.5-T magnet system (Magnetom Espree, Siemens) with the use of a body matrix coil. First, coronal and transverse proton density (PD) weighted images (TR/TE, 3000/30 ms; FOV, 220-240 mm; slice thickness, 5 mm; matrix, 333 × 512) were obtained. Subsequently, coronal and transverse proton density fat saturation (PD-FS) images were obtained (TR/TE, 3000+/30 ms; FOV, 220-320 mm; slice thickness, 3.5 mm; matrix, 326 × 512 [coronal] and 333 × 512 [transverse]).

MRI Assessment. Each MRI was assessed by 1 of 2 radiologists, each with more than 9 years of experience in musculoskeletal radiology (E.A. and M.M.). The radiologists were blinded as to whether the MRI was conducted at the time of the initial injury or at RTP. For assessment of the MRIs, we used standardized scoring forms based on the literature.[7,11,26,33,37] Increased T2 signal intensity (edema) for the affected hamstring muscle was measured in the craniocaudal, transverse, and anterior-posterior dimensions on fluid-sensitive sequences (STIR or PD-FS). We recorded the longitudinal length (craniocaudal) and

*Address correspondence to Gustaaf Reurink, MD, Erasmus Medical Center, Department of Orthopaedics, Erasmus Medical Centre, Room Hs-104, PO Box 2040, Rotterdam, 3000 CA, Netherlands (email: g.reurink@erasmusmc.nl).

†Department of Orthopaedics, Erasmus Medical Centre, Rotterdam, the Netherlands.

‡Department of Sports Medicine, The Sports Physicians Group, St Lucas Andreas Hospital, Amsterdam, the Netherlands.

§Department of Radiology, Aspetar Orthopaedic and Sports Medicine Hospital, Doha, Qatar.

‖Department of Sports Medicine, Aspetar Orthopaedic and Sports Medicine Hospital, Doha, Qatar.

¶High Performance Sport New Zealand, Millennium Institute of Sport and Health, Mairangi Bay, Auckland, New Zealand.

#Department of Sports Medicine, Bergman Clinics, Naarden, the Netherlands.

**Department of Radiology, Academic Medical Centre University of Amsterdam, Amsterdam, the Netherlands.

One or more of the authors has declared the following potential conflict of interest or source of funding: The Dutch randomized controlled trial was supported by the Royal Dutch Football Association and Arthrex Medizinische Instrumente GmbH.

TABLE 1
Eligibility Criteria[a]

Dutch Cohort	Qatari Cohort
Inclusion criteria	Inclusion criteria
• Age, 18-50 years	• Age, 18-50 years
• Clinical diagnosis of acute hamstring injury	• Acute onset of posterior thigh pain
• Initial MRI within 5 days of injury	• Initial MRI within 5 days of injury
• MRI-confirmed grade 1 or 2 hamstring lesionb	• MRI-confirmed grade 1 or 2 hamstring lesionb
• Second MRI within 1 week of RTP	• Second MRI within 1 week of RTP
Exclusion criteria	• Sex: male
• Contraindication for MRI	• Available to perform 5 sessions of physical therapy per week at the clinic
• Chronic hamstring injury	• Available for follow-up
• Chronic low back pain	Exclusion criteria
• Cause of injury is an extrinsic trauma	• Contraindication for MRI
• Not capable of performing rehabilitation	• Reinjury or chronic hamstring injury
• No intention to return to full sports activity	• Concurrent other injury inhibiting rehabilitation
• Unwilling to receive the intramuscular injections	• Unwilling to comply with follow-up
• Injection therapy received for this injury before	• Needle phobia
	• Overlying skin infection
	• Diabetes, immune-compromised state
	• Medication increasing bleeding risk (eg, clopidogrel)
	• Medical contraindication to injection

[a]MRI, magnetic resonance imaging; RTP, return to play.
[b]According to the modified Peetrons classification.[11,26]

calculated the involved cross-sectional area as a percentage of the total muscle cross-sectional area in the transverse plane. We measured the extent of low signal on T1-weighted images similarly in the 3 planes. We recorded the involved muscle(s) and performed grading of the injury using a modification of the Peetrons classification[11,26]: grade 0 = clinical diagnosis of an acute muscle injury without MRI abnormality, grade 1 = increased signal intensity on fluid-sensitive sequences without evidence of a macroscopic tear, grade 2 = increased signal intensity on fluid-sensitive sequences with a partial tear, and grade 3 = total muscle or tendon rupture. Increased signal intensity was defined as an abnormally increased signal in the intramuscular tissue compared with the unaffected surrounding muscle tissue. Low signal intensity was defined as abnormally low signal intensity in the intramuscular tissue compared with the surrounding muscle tissue.

Fibrosis

We defined fibrosis as an area of abnormally low signal intensity in the intramuscular tissue compared with the surrounding muscle tissue on all sequences (T1-weighted, T2-weighted, and STIR or PD-FS).[16,21] We used the T1-weighted images to measure the extent of the low signal intensity. A low signal intensity that presented as a rim around a collection of fluid (high signal on fluid-sensitive sequences) was not considered as fibrosis, as this is the typical appearance of a hematoma with a dark rim of hemosiderin deposition.[16]

Reinjury

Subjects were followed for reinjuries until 1 year after onset of the initial injury. In the Dutch cohort, players were advised to immediately contact the coordinating researcher in the event of a suspicion of reinjury, and reinjury occurrence was monitored at 4, 8, 16, 26, and 52 weeks with telephone calls to the subjects. Acute onset of posterior thigh pain that occurred at the same side as the initial injury and caused absence from play was recorded as a reinjury.[10] In the Qatari cohort, reinjury occurrence was monitored monthly with telephone calls to the subjects; in the event of a clinical suspicion of reinjury, the player was advised to immediately consult the study center. Acute hamstring injuries in the same leg were classified as reinjuries.

Statistical Analysis

We performed all statistical analysis with SPSS software (version 20.0; IBM Corp). We used descriptive statistics to present the patient and MRI characteristics. Parametric data are presented as mean and standard deviation, and nonparametric data are presented as median and interquartile range (IQR).

We analyzed the association between the MRI findings at RTP and reinjuries with a Cox proportional hazards regression model. In this model, the time (days) from return to play to the event (reinjury) or the end of the follow-up is the main variable. Subjects who sustained a severe injury (causing absence from training and matches >28 days[10,14]) during follow-up that was not considered a hamstring reinjury were censored at the time of this injury. Subjects lost to follow-up were censored at the time of their last available follow-up. Subjects completing the 1-year follow-up were censored at the time of the last follow-up measure. Time-to-reinjury curves were calculated with the Kaplan-Meier method.

We first analyzed the association between presence of fibrous tissue on MRI at RTP and reinjuries in an univariate

TABLE 2
Patient and Injury Characteristics[a]

	All Patients (N = 108)	Dutch Cohort (n = 63)	Qatari Cohort (n = 45)
Age, y, mean ± SD	28 ± 7	29 ± 7	26 ± 6
Sex, male/female	105 (97)/3 (3)	60 (95)/3 (5)	45 (100)/0 (0)
Sports			
Football	76 (70)	45 (71)	31 (69)
Field hockey	12 (11)	10 (16)	2 (4)
Futsal (indoor football)	9 (8)	1 (2)	8 (18)
Track and field	5 (5)	4 (5)	1 (2)
Other	6 (5)	3 (5)	3 (7)
Level of sports			
Professional	44 (41)	0 (0)	44 (98)
Competitive	48 (44)	48 (76)	0 (0)
Recreational	16 (15)	15 (24)	1 (2)
Ipsilateral hamstring injury in previous 12 mo	22 (20)	18 (29)	4 (9)
MRI characteristics of initial injury			
Primary injured muscle			
Biceps femoris long head	88 (82)	56 (89)	32 (71)
Biceps femoris short head	0 (0)	0 (0)	0 (0)
Semimembranosus	16 (15)	5 (8)	11 (24)
Semitendinosus	4 (4)	2 (3)	2 (4)
Injury classification, grade 1/grade 2[b]	45 (43)/63 (57)	18 (29)/45 (71)	45 (43)/63 (57)
T2-hyperintesity, median [IQR]			
Cross-sectional area, % of total muscle	28 [10-49]	37 [15-53]	18 [8-39]
Longitudinal length cm	12.9 [8.3-17.6]	11.0 [6.6-15.4]	15.0 [6.6-22.3]
Intramuscular fibrosis			
Absent	96 (89)	53 (84)	43 (96)
Present	12 (11)	10 (16)	2 (4)

[a]Values are reported as n (%) unless otherwise indicated. IQR, interquartile range; MRI, magnetic resonance imaging.
[b]According to modified Peetrons classification.[11,26]

model. Additionally, we performed a multivariate analysis in which we adjusted for ipsilateral hamstring injuries in the preceding 12 months and the cohort of the subject (Dutch or Qatari). We decided a priori to adjust for these variables, because a history of hamstring injury was previously reported as a predictor for reinjury[9,40] and because patients from 2 different cohorts may potentially lead to bias. We considered $P < .05$ to be statistically significant.

RESULTS

Between November 2009 and July 2014, we included 108 consecutive patients in the analysis. Patient characteristics and MRI findings of the initial injury obtained within 5 days after injury are presented in Table 2. The median time to RTP was 30 days (IQR, 22-42 days). The median time between the second MRI and RTP was 2 days (IQR, 0-4 days). The median time between the initial injury and MRI at RTP was 32 days (IQR, 23-46).

No patients were lost to follow-up. During follow-up after RTP, 4 patients sustained an injury that was not considered a reinjury but caused absence from training and matches more than 28 days, and these patients were censored in the survival analysis at the time of this injury. Of these 4 censored patients, there was 1 contralateral hamstring injury, 1 knee sprain, 1 ankle fracture, and 1 hip labral injury.

Findings of Fibrosis on MRI at RTP

Abnormally low signal intensity in the intramuscular tissue, suggestive of fibrosis, was present in 38% of the follow-up MRIs obtained at RTP. Typical examples of fibrosis seen on MRI are shown in Figures 1 and 2. The characteristics of the low signal intensity findings on MRI are presented in Table 3.

Association of Fibrosis With Reinjury

There were 26 reinjuries during the follow-up, 19 of 63 (30%) in the Dutch cohort and 7 of 45 (16%) in the Qatari cohort. Of these, 25 (96%) of the initial injuries were located in the biceps femoris and 1 (4%) in the semimembranosus. Sixteen of 67 (24%) subjects without fibrosis on MRI and 10 of 41 (24%) subjects with fibrosis on MRI sustained a reinjury. The cumulative incidences of the reinjuries of subjects with and without fibrosis are presented in Figure 3. The univariate Cox regression showed no significant association of MRI-detected fibrosis with reinjury, as the hazard ratio was 0.95 (95% CI, 0.43-2.1; $P = .898$). In the multivariate analysis, the hazard ratio adjusted for ipsilateral injuries in the preceding 12 months and the cohort of the subjects was 1.3 (95% CI, 0.55-2.8; $P = .591$).

TABLE 3
Characteristics of Abnormally Low Signal Intensity in the Intramuscular Tissue (Fibrous Tissue) on MRI Within 7 Days of RTP[a]

	All Patients (N = 108)	Patients Without Reinjury (n = 82; 76%)	Patients With Reinjury (n = 26; 24%)
Intramuscular fibrosis, n (%)			
Absent	67 (62)	51 (62)	16 (62)
Present	41 (38)	31 (38)	10 (38)
Muscle with fibrosis, n (%)			
Biceps femoris long head	36 (88)	26 (84)	10 (100)
Semimembranosus	5 (12)	5 (16)	0 (0)
Semitendinosus	0 (0)	0 (0)	0 (0)
Extent of fibrosis,[b] median [IQR]			
Longitudinal length, cm	5.8 [3.3-12.5]	6.5 [4.0-14.5]	3.3 [2.5-7.8]
Length on axial view, cm	1.0 [0.6-1.3]	1.0 [0.7-1.4]	0.7 [0.5-1.5]
Width on axial view, cm	0.5 [0.3-0.7]	0.5 [0.3-0.7]	0.4 [0.2-0.6]
Volume, cm^3	1.5 [0.5-3.9]	2.0 [0.7-3.9]	0.4 [0.2-4.2]

[a]IQR, interquartile range; MRI, magnetic resonance imaging; RTP, return to play.
[b]Measured on T1-weighted images.

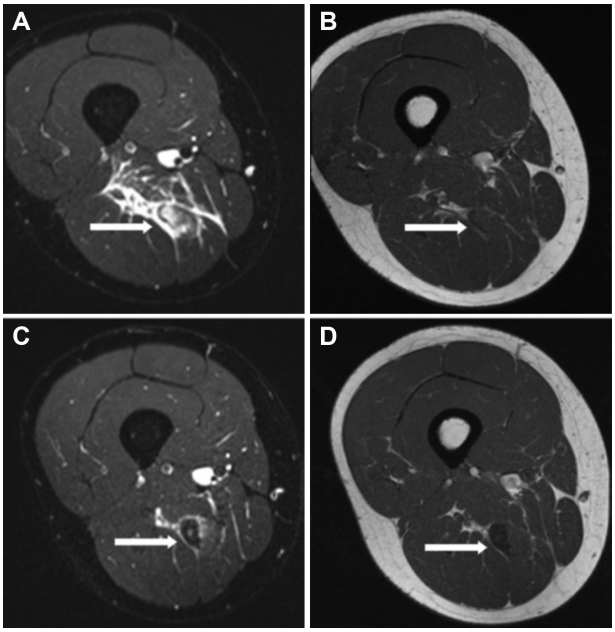

Figure 1. (A and B) Images of the initial injury: semimembranosus. The short-tau inversion recovery (STIR) image (A) shows increased signal intensity at the musculotendinous junction of the semimembranosus muscle (arrow). (C and D) Images at return to play 50 days after the initial injury. Both (C) STIR and (D) T1-weighted images showing an extensive area of low signal intensity, indicating fibrous tissue formation (arrow). The fluid-sensitive STIR image (C) shows a halo of increased signal intensity around the area of low signal.

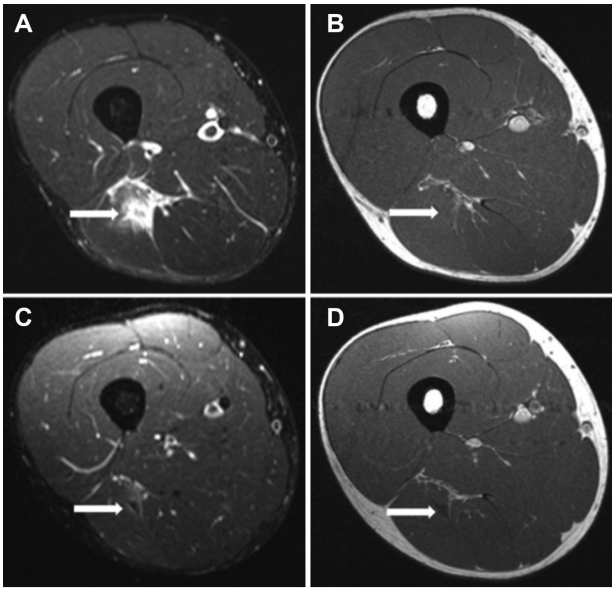

Figure 2. (A and B) Images of the initial injury: biceps femoris. The short-tau inversion recovery (STIR) image (A) shows increased signal intensity at the musculotendinous junction of the biceps femoris muscle (arrow). (C and D) Images at return to play 34 days after the initial injury. Both (C) STIR and (D) T1-weighted images show a small area of low signal intensity, indicating fibrous tissue formation (arrow). The fluid-sensitive STIR image (C) shows a halo of increased signal intensity around the area of low signal.

DISCUSSION

We found no association between fibrosis at RTP and reinjury risk after acute grades 1 and 2 hamstring injury. This is the first clinical study examining the association between MRI-detected fibrosis and reinjury risk in acute muscle injury. The finding that fibrosis on MRI at RTP is not associated with reinjury risk is clinically relevant, as it is a common finding at RTP (38% in this study), and fibrosis has historically been considered an important predisposing factor for reinjury.[13,17-19,33,34]

Silder et al[34] showed that postinjury fibrosis alters muscle contraction mechanics and may therefore theoretically predispose to injury. Using a dynamic MRI technique, the investigators measured muscle tissue velocities in

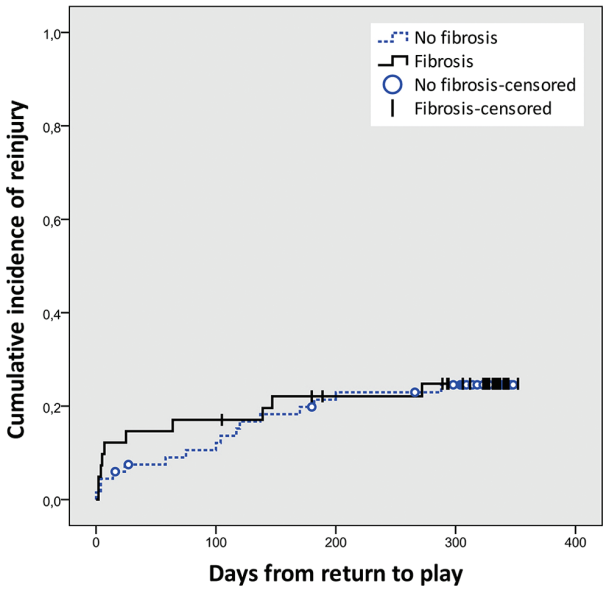

Figure 3. Inverse Kaplan-Meier curves showing the cumulative incidence of reinjury for subjects with MRI detected fibrosis (solid line) and subjects without MRI detected fibrosis (dashed line).

previously injured subjects with MRI-confirmed fibrosis of the proximal musculotendinous junction of the biceps femoris and compared these with healthy controls. The previously injured subjects had significantly greater tissue strain near the proximal musculotendinous junction than the controls.[34] In another study, Silder et al[36] found no correlation between the amount of fibrosis observed on MRI and either strength measures, running kinematics, or muscle activation patterns. To what extent these functional outcome measures are associated with hamstring injury risk remains unknown, but these findings together with the results of the current study challenge the role of fibrosis in predisposing to reinjury.

In our study, the MRI at RTP was performed at a median of 32 days (IQR, 23-46 days) after the injury. During the healing process after injury, the size of the fibrous tissue changed over time, initially occurring 2 to 3 days after injury and diminishing in size from around the third week. Scarring has been reported to persist up to 12 months after injury.[19] With our MRI observations at RTP, it remains unknown to what extent fibrosis persists in the long term. We cannot exclude that these observations simply reflect normal healing and subsequently disappear. Therefore, whether persisting residual fibrous tissue predisposes to reinjuries remains unknown and should be established in future studies. We recommend studying the time course of fibrosis in a prospective cohort study with repeated MRI follow-up for at least 1 year after injury.

We defined a reinjury as "an acute onset of posterior thigh pain that occurred at the same side as the initial injury and caused absence from play." However, the definition of a hamstring reinjury is debatable: Should a reinjury involve the same leg, the same muscle, and/or the same site within the muscle-tendon complex as the index injury? Can you consider an injury at a different location within the same hamstring muscle group as the index injury or as an additional injury? We argue that the hamstring muscle group acts as one functional anatomic unit and that a reinjury at a different location within the same muscle cannot be considered to be independent of the index injury. We therefore classify each acute hamstring injury that occurs in the same leg as the index injury as a reinjury. This definition is in accordance with the recommendation on injury definitions in studies of football injuries from the Injury Consensus Group under the auspices of the FIFA (Fédération Internationale de Football Association) Medical Assessment and Research Centre[12] and is applied in the current literature on hamstring injuries.[9-11,27-29,35] Additionally, this definition reflects what is experienced by the athlete and the medical staff: an injury to the same hamstring that keeps the player out of play.

As we did not perform MRI of the reinjury, it remains unknown to what extent reinjury occurs at the same site within the hamstring muscle group as the index injury. This could be assessed in future research.

Strengths and Limitations

The methodological strengths of our study include the prospective study design, the minimization of bias by blinding of the radiologists, the relatively long-term follow-up of 1 year, and the use of multivariate analysis to correct for potential confounding of previous injury and confounding of the use of 2 different cohorts.

Our study also has some limitations. First, the subjects were participants in 2 randomized controlled trials on the effect of platelet-rich plasma injections in grade 1 and 2 injuries. The effect of these injections on muscle healing is still unknown. Some investigators suggest a potential fibrotic effect of transforming growth factor–β1, one of the platelet-derived growth factors.[5,13]

Second, we analyzed 2 cohorts with some differences in MRI protocols and in criteria for clearance for RTP. This can be considered a limitation of the study, although it actually increases the external validity and generalizability for clinical practice where heterogeneous RTP criteria and MRI protocols are used. Adjusting for the cohort of the subjects in the analysis did not significantly change the outcome (hazard ratio).

Third, although low signal intensity in the intramuscular tissue on MRI is generally considered to reflect fibrous tissue,[20,21,33,34] the exact nature of this low signal intensity is unknown, as correlation with histopathological data is lacking.

Fourth, no data are available on the reliability of assessing low signal intensities (fibrosis) on MRI. Measures of increased signal intensity (edema) on MRI have excellent inter- and intraobserver reliability,[15] but the extent to which this can be generalized to the assessment of low signal intensities remains unknown.

Fifth, although the number of subjects and reinjuries is relatively large compared with previously published series on hamstring injuries,[3,30,35,39,40] with 26 reinjuries only a moderate to strong association between fibrosis and reinjury could be detected.[4] To detect a weaker

association, a larger sample size is required. To show a small to moderate association, 200 reinjuries would be needed.[4] Considering that the reinjury rate in the current study was 24%, this would require more than 800 subjects. However, large sample sizes can lead to statistically significant, but clinically irrelevant, weak associations.

In conclusion, fibrosis on MRI at RTP after grade 1 or 2 hamstring injuries is not associated with reinjury risk.

ACKNOWLEDGMENT

The authors thank Sirine Boukarroum for her efforts in the data collection.

REFERENCES

1. Alonso J-M, Edouard P, Fischetto G, Adams B, Depiesse F, Mountjoy M. Determination of future prevention strategies in elite track and field: analysis of Daegu 2011 IAAF Championships injuries and illnesses surveillance. *Br J Sports Med*. 2012;46(7):505-514.
2. Askling CM, Tengvar M, Saartok T, Thorstensson A. Acute first-time hamstring strains during high-speed running: a longitudinal study including clinical and magnetic resonance imaging findings. *Am J Sports Med*. 2007;35(2):197-206.
3. Askling CM, Tengvar M, Thorstensson A. Acute hamstring injuries in Swedish elite football: a prospective randomised controlled clinical trial comparing two rehabilitation protocols. *Br J Sports Med*. 2013;47(15):953-959.
4. Bahr R, Holme I. Risk factors for sports injuries—a methodological approach. *Br J Sports Med*. 2003;37(5):384-392.
5. Bedair HS, Karthikeyan T, Quintero A, Li Y, Huard J. Angiotensin II receptor blockade administered after injury improves muscle regeneration and decreases fibrosis in normal skeletal muscle. *Am J Sports Med*. 2008;36(8):1548-1554.
6. Brooks JHM, Fuller CW, Kemp SPT, Reddin DB. Incidence, risk, and prevention of hamstring muscle injuries in professional rugby union. *Am J Sports Med*. 2006;34(8):1297-1306.
7. Connell DA, Schneider-Kolsky ME, Hoving JL, et al. Longitudinal study comparing sonographic and MRI assessments of acute and healing hamstring injuries. *AJR Am J Roentgenol*. 2004;183(4):975-984.
8. De Visser HM, Reijman M, Heijboer MP, Bos PK. Risk factors of recurrent hamstring injuries: a systematic review. *Br J Sports Med*. 2012;46(2):124-130.
9. De Vos R-J, Reurink G, Goudswaard G-J, Moen MH, Weir A, Tol JL. Clinical findings just after return to play predict hamstring re-injury, but baseline MRI findings do not. *Br J Sports Med*. 2014;48(18):1377-1384.
10. Ekstrand J, Hägglund M, Waldén M. Epidemiology of muscle injuries in professional football (soccer). *Am J Sports Med*. 2011;39(6):1226-1232.
11. Ekstrand J, Healy JC, Waldén M, Lee JC, English B, Hägglund M. Hamstring muscle injuries in professional football: the correlation of MRI findings with return to play. *Br J Sports Med*. 2012;46(2):112-117.
12. Fuller CW, Ekstrand J, Junge A, et al. Consensus statement on injury definitions and data collection procedures in studies of football (soccer) injuries. *Br J Sports Med*. 2006;40(3):193-201.
13. Gharaibeh B, Chun-Lansinger Y, Hagen T, et al. Biological approaches to improve skeletal muscle healing after injury and disease. *Birth Defects Res C Embryo Today*. 2012;96(1):82-94.
14. Hägglund M, Waldén M, Ekstrand J. Previous injury as a risk factor for injury in elite football: a prospective study over two consecutive seasons. *Br J Sports Med*. 2006;40(9):767-772.
15. Hamilton B, Whiteley R, Almusa E, Roger B, Geertsema C, Tol JL. Excellent reliability for MRI grading and prognostic parameters in acute hamstring injuries. *Br J Sports Med*. 2014;48(18):1385-1387.
16. Hayashi D, Hamilton B, Guermazi A, de Villiers R, Crema MD, Roemer FW. Traumatic injuries of thigh and calf muscles in athletes: role and clinical relevance of MR imaging and ultrasound. *Insights Imaging*. 2012;3(6):591-601.
17. Heiderscheit BC, Sherry MA, Silder A, Chumanov ES, Thelen DG. Hamstring strain injuries: recommendations for diagnosis, rehabilitation, and injury prevention. *J Orthop Sports Phys Ther*. 2010;40(2):67-81.
18. Järvinen TAH, Järvinen TLN, Kääriäinen M, et al. Muscle injuries: optimising recovery. *Best Pract Res Clin Rheumatol*. 2007;21(2):317-331.
19. Kääriäinen M, Järvinen T, Järvinen M, Rantanen J, Kalimo H. Relation between myofibers and connective tissue during muscle injury repair. *Scand J Med Sci Sports*. 2000;10(6):332-337.
20. Koulouris G, Connell D. Hamstring muscle complex: an imaging review. *Radiographics*. 2005;25(3):571-586.
21. Lee JC, Mitchell AWM, Healy JC. Imaging of muscle injury in the elite athlete. *Br J Radiol*. 2012;85(1016):1173-1185.
22. Mendiguchia J, Brughelli M. A return-to-sport algorithm for acute hamstring injuries. *Phys Ther Sport*. 2011;12(1):2-14.
23. Orchard J, Best TM, Verrall GM. Return to play following muscle strains. *Clin J Sport Med*. 2005;15(6):436-441.
24. Orchard J, Seward H. Epidemiology of injuries in the Australian Football League, seasons 1997-2000. *Br J Sports Med*. 2002;36(1):39-44.
25. Orchard JW, Seward H, Orchard JJ. Results of 2 decades of injury surveillance and public release of data in the Australian Football League. *Am J Sports Med*. 2013;41(4):734-741.
26. Peetrons P. Ultrasound of muscles. *Eur Radiol*. 2002;12(1):35-43.
27. Petersen J, Thorborg K, Nielsen MB, Budtz-Jørgensen E, Hölmich P. Preventive effect of eccentric training on acute hamstring injuries in men's soccer: a cluster-randomized controlled trial. *Am J Sports Med*. 2011;39(11):2296-2303.
28. Reurink G, Goudswaard GJ, Moen MH, et al. Platelet-rich plasma injections in acute muscle injury. *N Engl J Med*. 2014;370(26):2546-2547.
29. Reurink G, Goudswaard GJ, Tol JL, et al. MRI observations at return to play of clinically recovered hamstring injuries. *Br J Sports Med*. 2014;48(18):1370-1376.
30. Reurink G, Goudswaard GJ, Tol JL, Verhaar JAN, Weir A, Moen MH. Therapeutic interventions for acute hamstring injuries: a systematic review. *Br J Sports Med*. 2012;46(2):103-109.
31. Sanfilippo JL, Silder A, Sherry MA, Tuite MJ, Heiderscheit BC. Hamstring strength and morphology progression after return to sport from injury. *Med Sci Sports Exerc*. 2013;45(3):448-454.
32. Sherry MA, Best TM. A comparison of 2 rehabilitation programs in the treatment of acute hamstring strains. *J Orthop Sports Phys Ther*. 2004;34(3):116-125.
33. Silder A, Heiderscheit BC, Thelen DG, Enright T, Tuite MJ. MR observations of long-term musculotendon remodeling following a hamstring strain injury. *Skeletal Radiol*. 2008;37(12):1101-1109.
34. Silder A, Reeder SB, Thelen DG. The influence of prior hamstring injury on lengthening muscle tissue mechanics. *J Biomech*. 2010;43(12):2254-2260.
35. Silder A, Sherry MA, Sanfilippo J, Tuite MJ, Hetzel SJ, Heiderscheit BC. Clinical and morphological changes following 2 rehabilitation programs for acute hamstring strain injuries: a randomized clinical trial. *J Orthop Sports Phys Ther*. 2013;43(5):284-299.
36. Silder A, Thelen DG, Heiderscheit BC. Effects of prior hamstring strain injury on strength, flexibility, and running mechanics. *Clin Biomech*. 2010;25(7):681-686.
37. Slavotinek JP, Verrall GM, Fon GT. Hamstring injury in athletes: using MR imaging measurements to compare extent of muscle injury with amount of time lost from competition. *AJR Am J Roentgenol*. 2002;179(6):1621-1628.
38. Tol JL, Hamilton B, Eirale C, Muxart P, Jacobsen P, Whiteley R. At return to play following hamstring injury the majority of professional football players have residual isokinetic deficits. *Br J Sports Med*. 2014;48(18):1364-1369.
39. Verrall GM, Slavotinek JP, Barnes PG, Fon GT. Diagnostic and prognostic value of clinical findings in 83 athletes with posterior thigh injury: comparison of clinical findings with magnetic resonance imaging documentation of hamstring muscle strain. *Am J Sports Med*. 2003;31(6):969-973.
40. Warren P, Gabbe BJ, Schneider-Kolsky M, Bennell KL. Clinical predictors of time to return to competition and of recurrence following hamstring strain in elite Australian footballers. *Br J Sports Med*. 2010;44(6):415-419.

For reprints and permission queries, please visit SAGE's Web site at http://www.sagepub.com/journalsPermissions.nav